Journal of Applied Biomechanics, 2013, 29, 371-379

Journal of
APPLIED BIOMECHANICS
An Official Journal of ISB
www.JAB-Journal.com
ORIGINAL RESEARCH

Humeral Head Translation After a Suprascapular Nerve Block

Jun G. San Juan,[1] Peter Kosek,[2] and Andrew R. Karduna[3]
[1]Tensegrity Physical Therapy, Eugene, OR; [2]Pain Consultants of Oregon; [3]University of Oregon

Subacromial impingement syndrome is the most common shoulder disorder. Abnormal superior translation of the humeral head is believed to be a major cause of this pathology. The first purpose of the study was to examine the effects of suprascapular nerve block on superior translation of the humeral head and scapular upward rotation during dynamic shoulder elevation. The secondary purpose was to assess muscle activation patterns during these motions. Twenty healthy subjects participated in the study. Using fluoroscopy and electromyography, humeral head translation and muscle activation were measured before and after a suprascapular nerve block. The humeral head was superiorly located at 60 degrees of humeral elevation, and the scapula was more upwardly rotated from 30 to 90 degrees of humeral elevation after the block. The differences were observed during midrange of motion. In addition, the deltoid muscle group demonstrated increased muscle activation after the nerve block. The study's results showed a compensatory increase in humeral head translation, scapular upward rotation, and deltoid muscle activation due to the nerve block. These outcomes suggest that increasing muscular strength and endurance of the supraspinatus and infraspinatus muscles could prevent any increased superior humeral head translation. This may be beneficial in reducing shoulder impingement or rotator cuff tears over time.

Keywords: glenohumeral kinematics, rotator cuff, superior translation, electromyography

Shoulder impingement and rotator cuff tears are among the most common chronic shoulder injuries in the general population and in athletes involved in overhead throwing sports.[1,11,14,21,37,48,49] Weak or dysfunctional rotator cuff musculature may change both glenohumeral and scapular kinematics.[27] These changes include increased superior humeral head translation[4,38,41,43] and greater scapular upward rotation.[10,20,45] Over time, if these alterations are left untreated, they may lead to more debilitating shoulder pathologies, such as rotator cuff tears.

Although there clearly are underlying biological factors involved, many clinicians feel that abnormal mechanical forces may lead to a progression from impingement syndrome, or tendonitis, to rotator cuff tears. Since patient data are rarely available before the development of cuff tears, it is not known whether increased superior translation of the humeral head is causal or compensatory in nature.

Scapular upward rotation is the predominant motion of the scapula.[27] It allows the acromion to elevate during glenohumeral elevation and appears to prevent impingement under the acromion.[11] Studies have shown that altered scapular upward rotation has been associated with individuals suffering from shoulder impingement.[20,23] In addition, differences in upward rotation have been observed with in vivo models that attempted to mimic shoulder muscle dysfunction.[9,24]

Changes in humeral head translation have been observed in patients with rotator cuff tears and shoulder impingement.[3,8,28,29,50] When compared with asymptomatic controls, patients with rotator cuff tears demonstrated greater humeral head translation during shoulder elevation, especially during the midranges of motion.[8,50] The geometric center of the humeral head was more superiorly located with respect to the center of the glenoid fossa.

Suprascapular nerve blocks are commonly performed clinically for relief of shoulder pain that is due to conditions such as adhesive capsulitis and nerve entrapment.[15,35,40] However, several investigators have taken advantage of this nerve's innervation to perform nerve block studies for biomechanical evaluations of strength[5,12,18] and kinematics.[13] Due to the compressive functions of both the supraspinatus and infraspinatus muscles, interventions that result in dysfunction of these muscles are candidate models for rotator cuff pathology. Since the suprascapular nerve innervates both the supraspinatus and infraspinatus, a suprascapular nerve block was used to achieve dysfunction of these muscles.

There were two goals of the current study. The first was to examine the effects of a suprascapular nerve block

Jun G. San Juan *(Corresponding Author)* is with Tensegrity Physical Therapy, Eugene, OR. Peter Kosek is with the Department of Human Physiology, University of Oregon, Eugene, OR. Andrew R. Karduna is with Pain Consultants of Oregon, Eugene, OR.

on superior translation of the humeral head and scapular upward rotation during dynamic shoulder elevation, and the second was to assess muscle activation patterns during these motions. The authors hypothesized that a suprascapular nerve block would result in a compensatory increase in superior translation of the humeral head and greater scapular upward rotation. In addition, the authors hypothesized a compensatory increase in deltoid and latissimus dorsi muscle activation after the block.

Methods

Subjects

Twenty healthy subjects volunteered for the study, 10 males and 10 females (age 25 ± 5 y, height 171.4 ± 6.7 cm, weight 66.9 ± 10.1 kg). A sample size calculation based on data from Sharkey and Marder,[36] revealed that 17 subjects can detect a minimum power of 0.8. Subject exclusion criteria for the study were as follows: (1) less than 135° of active humeral elevation in the scapular plane; (2) prior shoulder surgery; (3) shoulder injury in the past six months; (4) presence of shoulder pain preventing the correct execution of tests; (5) any allergies to lidocaine; (6) history of cervical or shoulder pain or pathology; (7) women who were currently pregnant; (8) BMI greater than 30 kg/m^2 (threshold for obesity as defined by the CDC); and (9) height greater than 183 cm. The last restriction was due to a limitation with the fluoroscope. Approval for the study was obtained from University's Office for Protection of Human Subjects. Each subject signed a consent form.

Testing Protocol

All testing was completed in a single session and performed on the dominant upper extremity. Subjects performed a standardized shoulder warm-up procedure.[39] Following the warm-up procedure, subjects were fitted with a lead apron skirt to protect them from radiation. The testing protocol was thoroughly explained to the subject. Before data collection, practice trials were performed by the subjects. A calibration marker with a known length was positioned on the scapular spine to scale the digital images (Figure 1).

Subjects were asked to stand while performing normal shoulder elevation in the scapular plane before and following a suprascapular nerve block. Scapular plane orientation was defined as approximately 30–35° anterior to the coronal plane. Before each collection, with the help of real-time fluoroscopy, the investigator adjusted the subject's position so that the scapula was perpendicularly aligned to the field of view of the fluoroscope to avoid distortion of the glenoid cavity. In addition, the distance between the shoulder and the fluoroscopy machine remained constant for a given subject to minimize magnification errors. Shoulder elevation trials were collected using fluoroscopy with subjects standing

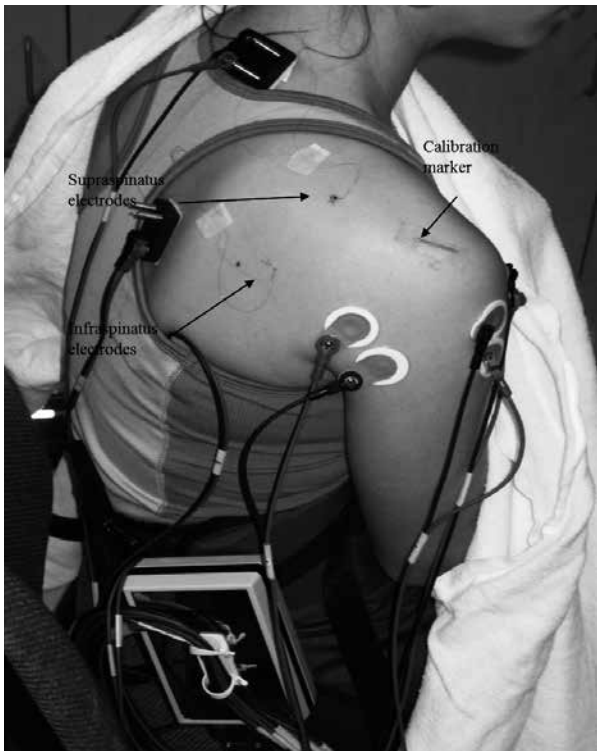

Figure 1 — Surface and fine-wire EMG setup.

at a marked position, eyes facing forward, elbow in full extension, and slight forearm pronation. Using a customized shoulder elevation guide, each subject was asked to elevate their arm as close as possible to this semicircular guide (Figure 2). The foot position was marked on the platform to maintain consistency within trials. The range of motion was subject dependent, but all trials began with the arm at the subject's side. Two shoulder elevation trials were collected before a suprascapular nerve block, and the best digital image quality between the two trials was used for analysis (NB0). The Space edge detection software (http://lcni.uoregon.edu/~dow/Space_program.html) (Lewis Center for Neuroimaging, University of Oregon, Eugene) was used to digitize the humeral head and glenoid face. If the software could detect the edges of both the humeral head and glenoid face of the elevation trial, it was considered to be of best quality. After the nerve block, nine shoulder elevation trials were collected. Nine elevation trials were collected because we wanted to see the effects of increasing function of the supraspinatus and infraspinatus after the nerve block on humeral head translation. However, for the purpose of this current research, only first (NB1) and last (NB2) trials were analyzed because only the 9th trial showed significant increase in external rotation torque production compare with the 1st trial after nerve block. The mean time between NB1 and NB2 was 56 minutes. To control the velocity of motion, audible counts of 4 s (8 s total) were used during both shoulder elevation and depression in the scapular plane. Each trial

Figure 2 — Subject setup during the elevation trial.

consisted of two shoulder elevations and one shoulder depression in the scapular plane. It took an average of 14 s of live fluoroscopic image acquisition for each trial. The average total range of motion during shoulder elevation was 0–160 degrees. Immediately following each shoulder motion trial, external rotation force measurements were collected. The time from the start of a trial to the start of the succeeding trial was 7 minutes. The actual elevation trial plus force measurement lasted for about 3 minutes.

Kinematic Measurements

Humeral head translation and scapular upward rotation were measured with the arm at the side (0°) and at 30°, 60°, 90°, and 120° of humeral elevation. A GE (OEC) 9800 fluoroscopy unit was used for collecting two-dimensional in vivo kinematics of the glenohumeral joint. The sampling rate was set at 8 Hz, which is the highest rate for this system. The fluoroscopy was set at a normal standard mode (59–72 kVp and 0.52–1.5 mA). The total amount of radiation that each subject received during the experiment was approximately equal to two dental x-rays. A standardized protocol was used when taking fluoroscopic images to regulate each data collection across subject and condition. The protocol was able to control focal point, magnification, and elevation velocity of the arm. During data collection, the subjects were asked to stand between the X-ray source and image intensifier of the C-arm.

Monitoring Muscle Activation and Force Measurements

Electromyography (EMG) data were collected to verify minimal muscle activation after suprascapular nerve block. In addition, muscle activation patterns before and after nerve block were analyzed. Kinematic measurements were synchronized with the EMG activity using an external trigger. The Myopac Jr. (Run Technologies, Mission Viejo, CA) was used to collect raw surface and fine-wire EMG data. This unit provided signal amplification, band pass filtering (10–1000 Hz), and a common mode rejection ratio of 110 dB. Output from the Myopac was linked to an analog-to-digital board in a laptop computer and data were collected at a frequency of 1200 Hz. Disposable Blue Sensor surface electrodes (Ambu Inc, Linthicum, MD) were placed over the anterior deltoid, middle deltoid, posterior deltoid, and latissimus dorsi muscles along their primary muscle fiber directions. Sterilized fine-wire electrodes (Chalgren Enterprise, Inc, Gilroy, CA) were inserted intramuscularly in the supraspinatus and infraspinatus muscles. To allow for normalization of EMG measures, EMG data were collected during a standard maximum voluntary contraction (MVC) for each muscle.

External rotation forces were measured with a Microfet 2 Manual Muscle Test (MMT) device (Hoggan Health, Ind, West Jordan, UT). The Microfet 2 MMT is a hand-held device used to objectively measure muscle strength. Schaubert and Bohannon[34] reported an ICC of 0.93 when using this device to measure muscle strength. Subjects were seated in a chair during force measurement. Since force measurement was performed before and after the nerve block, markers were placed on the area where the MMT was applied during data collection. This ensured consistency of the resistant moment arm. During force measurement, subjects were instructed to push as hard as they could against the MMT for 5 s while verbal encouragement was provided by the investigator. Raw data were collected at 60 Hz from the MMT device using a customized Microsoft Visual Basic (Microsoft, Redmond, WA) program connected to a laptop computer through a USB port. The data from 3 to 4 s were averaged and used for subsequent analysis. The MMT was positioned and held by the investigator on the designated part of the forearm. The testing positions was elbow flexed at 90°, thumb pointing up and shoulder externally rotated 5° with the arm at the side. This position of the arm was chosen because it has been reported to best isolate the infraspinatus muscle.[16,17]

Suprascapular Nerve Block

The suprascapular nerve block was performed by a board-certified anesthesiologist (PK). Subjects were asked to sit, with their head flexed forward, throughout the nerve blocking procedure. One inch above the junction of the middle and outer third of the scapular spine, the suprascapular nerve was targeted at the scapular notch through a skin wheel of 0.2 mL of 1% lidocaine. A total

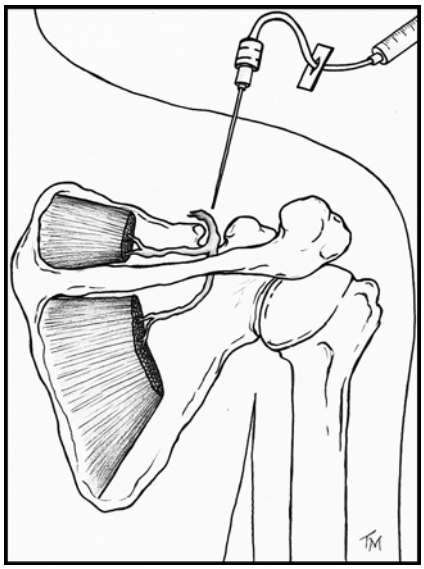

Figure 3 — An illustration of the suprascapular nerve block procedure.

of 40–100 mg of lidocaine was injected to the subject's nerve (Figure 3). Moreover, the first eight subjects had epinephrine (1:400,000) combined with the lidocaine to prolong the effects of the nerve block to more than 2 hours. However, since the average testing time after NB1 to NB2 was 56 minutes, the physician decided that adding the epinephrine to the nerve block was not warranted and the remaining 12 subjects had only the lidocaine injected. A time stamp was recorded, and a countdown timer was initiated, at the moment the needle was withdrawn. After 10 minutes following initial injection, external rotation (ER) force, and supraspinatus and infraspinatus EMG activity were measured. A reduction of 50% ER force and supraspinatus and infraspinatus MVC was the threshold needed to proceed to the post-block trials. We did not have any subject who failed these criteria.

Data Reduction and Analysis

Humeral head translation was measured using a 2-D registration technique developed by Crisco et al.[7] In addition, Figure 4 depicts the points that were digitized on the glenoid face, the humeral head, and the humeral shaft using Space edge detection software. Using the digitized points, the humeral head coordinates were then used to calculate the geometric center of the humeral head by using a curve-fitting, nonlinear regression analysis to fit a circle to the humeral head coordinate data, and then calculating the center point using a customized LabVIEW (National Instruments Corporation, Austin, TX) program. Humeral translation was defined as net translation of the humeral head, using both x and y components. Using the geometric center of the humeral head and the transformation matrix that was generated based on the contour registration between images, the net translation of the humerus and scapular rotation was calculated. The measured humeral head translation and scapular upward rotation were calculated by comparing the pre- and post-nerve-block trial in each humeral elevation angle with respect to the corresponding elevation angle during the pre–nerve block trial (ie, 30° humeral elevation pre–nerve block to 30° humeral elevation post–nerve block). This method of measuring humeral head translation was previously validated by the investigator with a measured error of less than 0.5 mm.[33] Using a customized LabVIEW (National Instruments Corporation, Austin, TX) program, humeral elevation angles were calculated with respect to the vertical axis and a straight line on the shaft of the humerus. The actual humeral elevation angles used for data analysis were off by an average of 3° from the target elevation angles.

A one-sample t test compared with zero was performed to test statistical significance between conditions. The two conditions were pre–nerve block (NB0) and post–nerve block (NB1 and NB2). Measured humeral head translation and scapular upward rotation with the arm at the side (0°) and at 30°, 60°, 90°, and 120° of humeral elevation served as the dependent variables. For the EMG activity, a one-way repeated-measures

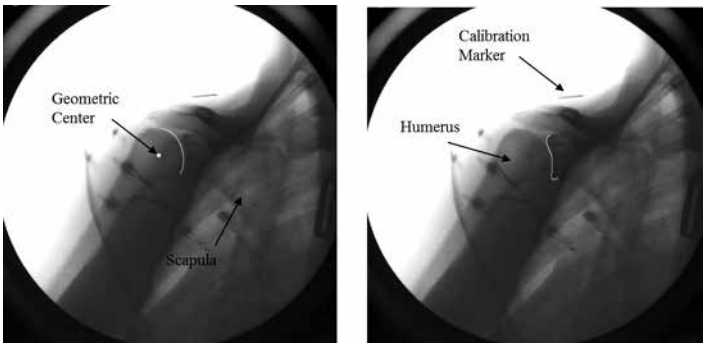

Figure 4 — Actual x-ray images with digitization of an arc at the humeral head and an illustration of the geometric center of the humeral head (A) and digitized glenoid used for contour registration (B).

ANOVA was used to compare differences between humeral elevation angles before and after the nerve block. All data were plotted as mean values ± standard error of the mean. The alpha level for all tests was set at .05.

Results

At 60° of humeral elevation, the humeral head was significantly more superiorly located for both NB1 and NB2 (Figure 5A, B). There was a significant increase in scapular upward rotation, at NB1 for humeral elevation angles of 30°, 60°, and 90° (Figure 5C). In contrast, NB2 did not show any significant differences across all humeral elevation angles (Figure 5D).

Only 19 subjects were included in the analysis of EMG activity due to synchronization problems with one of the subjects. The supraspinatus, infraspinatus, and middle deltoid demonstrated statistically significant differences from 30° to 120° of humeral elevation angles (Figure 6A, B, and D). The supraspinatus and infraspinatus had decreased muscle activation after the nerve block, whereas the anterior deltoid, middle deltoid, and posterior deltoid showed significant increases at higher humeral elevation angles. In addition, the deltoid muscle group had increased muscle activation during higher humeral elevation (Figure 6C, D, and E). The posterior deltoid (for NB2) was the only one that showed statistically significant differences when the arm was at the side (Figure 6E). The latissimus dorsi did not show any significant differences across all humeral elevation angles (Figure 6F).

Discussion

The current study supports our hypothesis that a suprascapular nerve block results in a compensatory increase in superior translation of the humeral head and greater scapular upward rotation at certain humeral elevation angles. For the current study, the authors chose to compare the before and after nerve block conditions at each corresponding humeral elevation angle with respect to the pre–nerve block (ie, 60° humeral elevation Pre-NB to 60° humeral elevation Post-NB). This was because the emphasis of the current study was to examine differences in measured humeral head translation and scapular upward rotation between conditions at specific humeral elevation angles. Previous studies that measured translation used the humeral head neutral position during the control condition as the reference point.[8,28,29,47] However, that approach would introduce additional errors with our 2-D registration technique.[7,33]

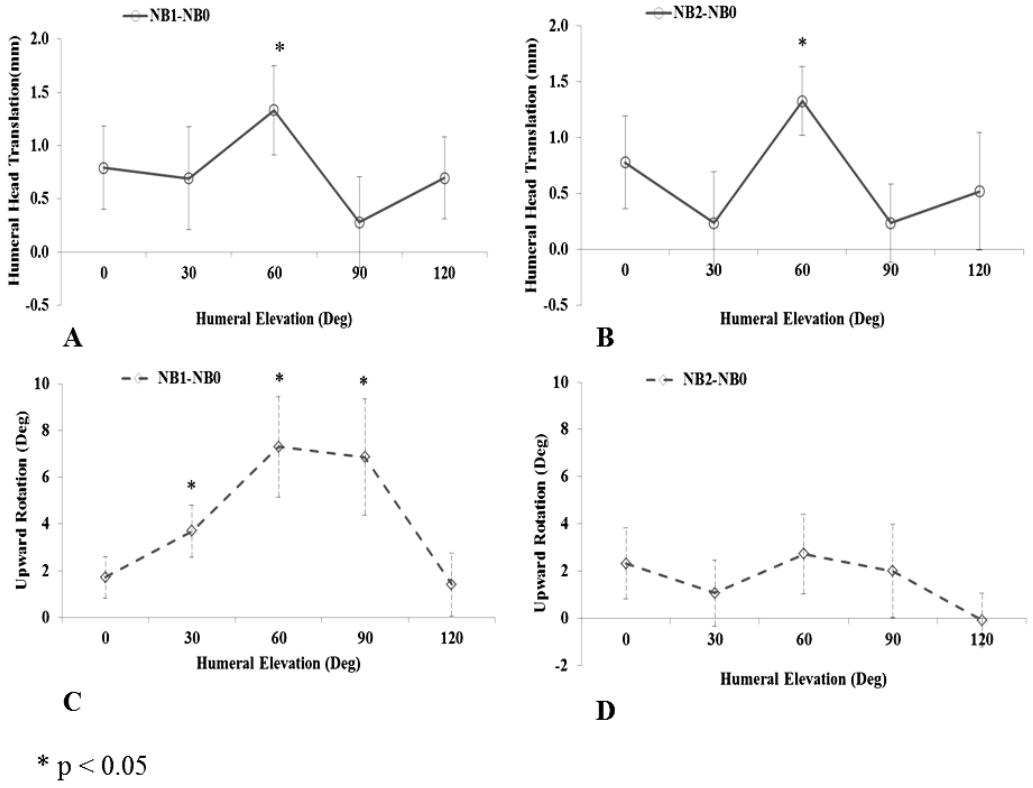

Figure 5 — Difference in measured humeral head translation. Positive numbers represent superior location of the humeral head after the nerve block and negative represents inferiorly located humeral head after the nerve block (A & B). C & D represents the scapular upward rotation. A positive number represents greater scapular upward rotation.

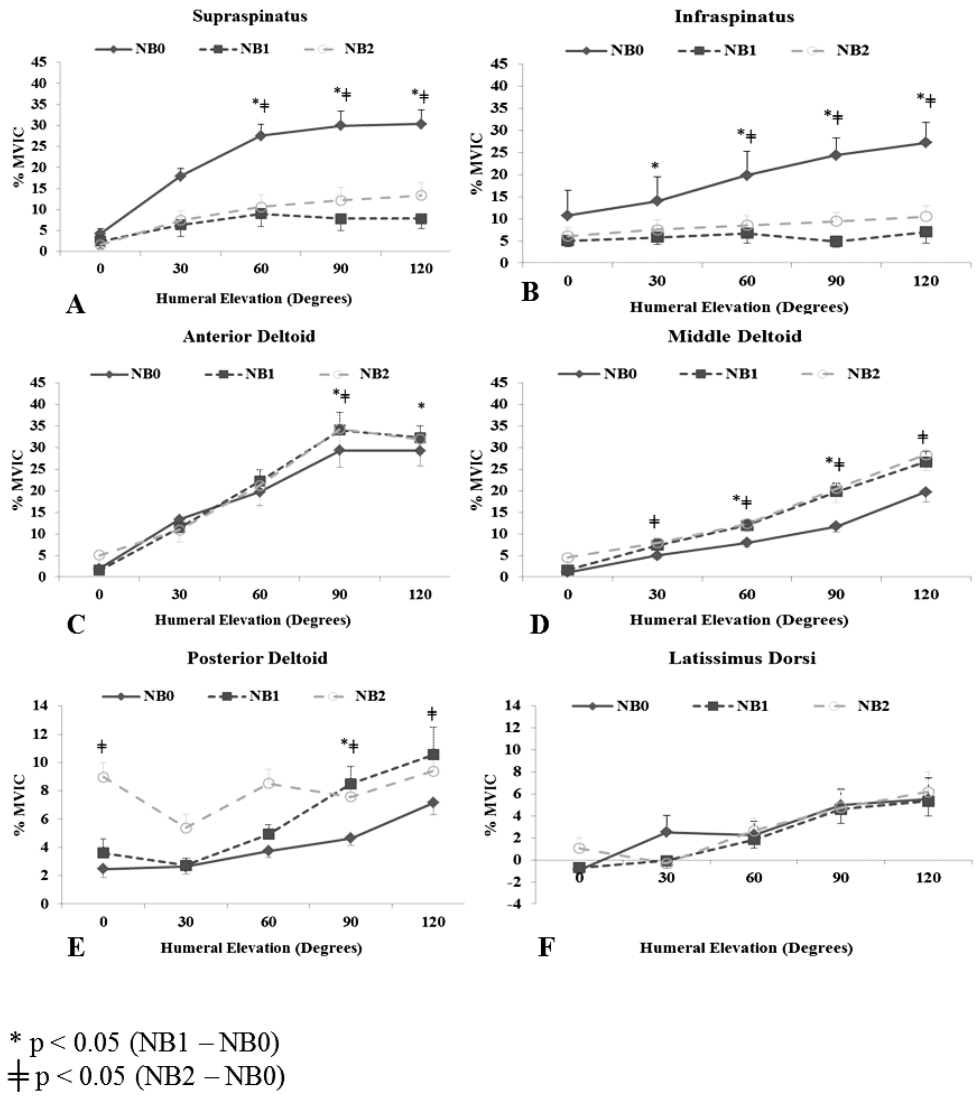

Figure 6 — EMG muscle activation of different shoulder muscles during humeral elevation. All three deltoid muscles showed significant increases in activation at 90 degrees of elevation at both time points after the nerve block.

The observed superior translations at 60° of humeral elevation in the current study are similar to the findings in patients with impingement and rotator cuff tears.[3,8,28,29,50] This provided evidence that there is a compensatory increase in humeral head translation during the midrange of motion after paralysis of supraspinatus and infraspinatus. In addition, in a more recent study by Teyhen et al,[42] the authors observed that the humeral head was superiorly located on the glenoid fossa during dynamic arm elevation. This result is in agreement with the current study. However, in a similar study performed by Werner et al,[47] they did not find any significant differences in measured humeral head translation after suprascapular nerve block. There are two possible reasons for the differences seen in measured translation. First, the reference point used by the current study was different. The current study used the corresponding humeral elevation angle of the pre–nerve block condition to compare translation of the humeral head whereas the latter study used the humeral head location in the neutral position as the reference. Second, the subjects were seated during arm elevation trials compared with the current study in which the subjects were standing. This difference in subject positioning could have influenced both glenohumeral and scapular kinematics during arm elevation.[30] Lastly, they tested 10 subjects whereas the current study collected and analyzed 20 subjects. The statistical analysis showed that to get a minimum power of 0.8, 17 subjects were needed.

The current study was designed to mimic rotator cuff dysfunction and not rotator cuff tears. The authors used suprascapular nerve block to paralyze the supraspinatus and infraspinatus. The result of the current study showed a more superiorly located humeral head after nerve block at 60° of humeral elevation with a mean value of 1.3

mm. This value is comparable to studies that measured humeral head translation and found significant differences. Chen et al,[4] using a muscle fatigue model, observed increased superior humeral head translation of 2.5 mm after the deltoid and rotator cuff were fatigued. Deutsch et al[8] reported superior translation of the humeral head equivalent to 1.2 mm with rotator cuff patients during humeral elevation. In a more recent study, Bey et al[2] reported observing superior translation of approximately 2.6 mm during shoulder elevation in subjects that had a surgically repaired supraspinatus tendon tear.

The current study had similar results seen in a related research design that was previously completed in our laboratory. That study also found a more upwardly rotated scapula at midranges of motion after the block.[24] Additionally, our results are similar to other studies that have examined scapular kinematics in rotator cuff patients compared with healthy individuals.[26,28,50] It is interesting to see increases in scapular upward rotation after paralysis of the supraspinatus and infraspinatus because contraction of these muscles is not responsible for any scapular motion. The is result may be due to the fact that the subjects experienced difficulty elevating their arm after suprascapular nerve block because the supraspinatus also functions to initiate humeral elevation.[46] Therefore, the subjects may have compensated by increasing the activation of the upper trapezius to help during humeral elevation, which induced greater upward rotation of the scapula. Studies have shown increases in upper trapezius activity during humeral elevation with shoulder impingement population.[6,19]

In addition, an increase in muscle activation was observed in all the deltoid muscles after 90° of humeral elevation. The middle deltoid showed increased muscle activation starting at 30° of elevation. This result is in accordance with Thompson et al,[44] who showed a significant increase in the middle deltoid force required to initiate abduction force after paralysis of supraspinatus in a cadaver. This might be due to the fact that it is compensating for the loss of abductor effect of the supraspinatus during the early stages of elevation. One of the main actions of the supraspinatus is to aid the deltoid in elevating the glenohumeral joint.[31] Moreover, McCully et al[25] showed increases in the deltoid muscle group after suprascapular nerve block.

It is important that the current study address the limitation of the 2-D imaging technique used to measure kinematics. Using a 2-D imaging technique to measure glenohumeral and scapular kinematics, which is a 3-dimensional motion, presents inherent projection error due to out-of-plane motions. To avoid out-of-plane motion, before each collection, with the help of real-time fluoroscopy, the investigator adjusted the subject's position so that the scapula was perpendicularly aligned to the field of view of the fluoroscope to avoid distortion of the glenoid cavity. In addition, the distance between the shoulder and the fluoroscopy machine remained constant for a given subject to minimize magnification errors. Shoulder elevation trials were collected using fluoroscopy with subjects standing at a marked position, eyes facing forward, elbow in full extension, and slight forearm pronation. Using a customized shoulder elevation guide, each subject was asked to elevate his or her arm as close as possible to this semicircular guide (Figure 2). The foot position was marked on the platform to maintain consistency within trials.

The result of the current study may have implications in designing rehabilitation and strengthening protocol for individuals with shoulder impingement, and individuals with weak or dysfunctional rotator cuff musculature. The current study showed that a dysfunctional supraspinatus and infraspinatus increased humeral head superior translation and scapular upward rotation during humeral elevation. Such changes in the glenohumeral and scapular kinematics have been associated with shoulder impingement.[20–22,32] Shoulder rehabilitation programs should focus on strengthening the supraspinatus and infraspinatus, which would be beneficial in reducing weak and dysfunctional rotator cuff muscles. In addition, this could help alleviate symptoms of shoulder impingement.

Acknowledgments

We thank Diana Raponi for technical assistance with the fluoroscopy. Partial funding for this project was provided by a grant from NIOSH: 5R01OH008288. In addition, we want to thank Traci San Juan for the illustration.

References

1. Almekinders LC. Impingement syndrome. *Clin Sports Med*. 2001;20:491–504. PubMed doi:10.1016/S0278-5919(05)70265-9
2. Bey MJ, Kline SK, Zauel R, Lock TR, Kolowich PA. Measuring dynamic in-vivo glenohumeral joint kinematics: technique and preliminary results. *J Biomech*. 2008;41:711–714. PubMed doi:10.1016/j.jbiomech.2007.09.029
3. Bezer M, Yildirim Y, Akgun U, Erol B, Guven O. Superior excursion of the humeral head: a diagnostic tool in rotator cuff tear surgery. *J Shoulder Elbow Surg*. 2005;14:375–379. PubMed doi:10.1016/j.jse.2004.12.001
4. Chen SK, Simonian PT, Wickiewicz TL, Otis JC, Warren RF. Radiographic evaluation of glenohumeral kinematics: a muscle fatigue model. *J Shoulder Elbow Surg*. 1999;8:49–52. PubMed doi:10.1016/S1058-2746(99)90055-1
5. Colachis SC, Jr, Strohm BR. Effect of suprascapular and axillary nerve blocks on muscle force in upper extremity. *Arch Phys Med Rehabil*. 1971;52:22–29. PubMed
6. Cools AM, Declercq GA, Cambier DC, Mahieu NN, Witvrouw EE. Trapezius activity and intramuscular balance during isokinetic exercise in overhead athletes with impingement symptoms. *Scand J Med Sci Sports*. 2007;17:25–33. doi:10.1111/j.1600-0838.2006.00570.x
7. Crisco JJ, Hentel K, Wolfe SW, Duncan JS. Two-dimensional rigid-body kinematics using image contour registration. *J Biomech*. 1995;28:119–124. PubMed doi:10.1016/0021-9290(95)80015-8
8. Deutsch A, Altchek DW, Schwartz E, Otis JC, Warren RF. Radiologic measurement of superior displacement of the humeral head in the impingement syndrome. *J Shoulder*

Elbow Surg. 1996;5:186–193. PubMed doi:10.1016/S1058-2746(05)80004-7
9. Ebaugh DD, McClure PW, Karduna AR. Effects of shoulder muscle fatigue caused by repetitive overhead activities on scapulothoracic and glenohumeral kinematics. *J Electromyogr Kinesiol*. 2006;16:224–235. PubMed
10. Ebaugh DD, McClure PW, Karduna AR. Scapulothoracic and glenohumeral kinematics following an external rotation fatigue protocol. *J Orthop Sports Phys Ther*. 2006;36:557–571. PubMed doi:10.2519/jospt.2006.2189
11. Flatow EL, Soslowsky LJ, Ticker JB, et al. Excursion of the rotator cuff under the acromion. Patterns of subacromial contact. *Am J Sports Med*. 1994;22:779–788. PubMed doi:10.1177/036354659402200609
12. Howell SM, Imobersteg M, Seger DH, Marone PJ. Clarification of the role of the supraspinatus muscle in shoulder function. *Journal of Bone and Joint Surgery*. 1986;68A:398–404. PubMed
13. Howell SM, Kraft TA. The role of the supraspinatus and infraspinatus muscles in glenohumeral kinematics of anterior shoulder instability. *Clin Orthop Relat Res*. 1991;(263):128–134. PubMed
14. Hulstyn MJ, Fadale PD. Shoulder injuries in the athlete. *Clin Sports Med*. 1997;16:663–679. PubMed doi:10.1016/S0278-5919(05)70047-8
15. Karatas GK, Meray J. Suprascapular nerve block for pain relief in adhesive capsulitis: comparison of 2 different techniques. *Arch Phys Med Rehabil*. 2002;83:593–597.
16. Kelly BT, Kadrmas WR, Kirkendall DT, Speer KP. Optimal normalization tests for shoulder muscle activation: an electromyographic study. *J Orthop Res*. 1996;14:647–653. PubMed doi:10.1002/jor.1100140421
17. Kuechle DK, Newman SR, Itoi E, Niebur GL, Morrey BF, An KN. The relevance of the moment arm of shoulder muscles with respect to axial rotation of the glenohumeral joint in four positions. *Clin Biomech (Bristol, Avon)*. 2000;15:322–329. PubMed doi:10.1016/S0268-0033(99)00081-9
18. Kuhlman JR, Iannotti JP, Kelly MJ, Riegler FX, Gevaert ML, Ergin TM. Isokinetic and isometric measurement of strength of external rotation and abduction of the shoulder. *J Bone Joint Surg Am*. 1992;74:1320–1333. PubMed
19. Lin JJ, Hsieh SC, Cheng WC, Chen WC, Lai Y. Adaptive patterns of movement during arm elevation test in patients with shoulder impingement syndrome. *J Orthop Res*. 2011;29:653–657. PubMed doi:10.1002/jor.21300
20. Ludewig PM, Cook TM. Alterations in shoulder kinematics and associated muscle activity in people with symptoms of shoulder impingement. *Phys Ther*. 2000;80:276–291. PubMed
21. Ludewig PM, Cook TM. Translations of the humerus in persons with shoulder impingement symptoms. *J Orthop Sports Phys Ther*. 2002;32:248–259. PubMed
22. Lukasiewicz AC, McClure P, Michener L, Pratt N, Sennett B. Comparison of 3-dimensional scapular position and orientation between subjects with and without shoulder impingement. *J Orthop Sports Phys Ther*. 1999;29:574–583; discussion 584–576.
23. McClure PW, Michener LA, Karduna AR. Shoulder function and 3-dimensional scapular kinematics in people with and without shoulder impingement syndrome. *Phys Ther*. 2006;86:1075–1090. PubMed
24. McCully SP, Suprak DN, Kosek P, Karduna AR. Suprascapular nerve block disrupts the normal pattern of scapular kinematics. *Clin Biomech (Bristol, Avon)*. 2006;21:545–553. doi:10.1016/j.clinbiomech.2006.02.001
25. McCully SP, Suprak DN, Kosek P, Karduna AR. Suprascapular nerve block results in a compensatory increase in deltoid muscle activity. *J Biomech*. 2007;40:1839–1846. doi:10.1016/j.jbiomech.2006.07.010
26. Mell AG, LaScalza S, Guffey P, et al. Effect of rotator cuff pathology on shoulder rhythm. *J Shoulder Elbow Surg*. 2005;14:S58–S64. PubMed doi:10.1016/j.jse.2004.09.018
27. Michener LA, McClure PW, Karduna AR. Anatomical and biomechanical mechanisms of subacromial impingement syndrome. *Clin Biomech (Bristol, Avon)*. 2003;18:369–379. PubMed doi:10.1016/S0268-0033(03)00047-0
28. Paletta GA, Jr, Warner JJ, Warren RF, Deutsch A, Altchek DW. Shoulder kinematics with two-plane x-ray evaluation in patients with anterior instability or rotator cuff tearing. *J Shoulder Elbow Surg*. 1997;6:516–527. PubMed doi:10.1016/S1058-2746(97)90084-7
29. Poppen NK, Walker PS. Normal and abnormal motion of the shoulder. *J Bone Joint Surg Am*. 1976;58:195–201. PubMed
30. Riek LM, Ludewig PM, Nawoczenski DA. Comparative shoulder kinematics during free standing, standing depression lifts and daily functional activities in persons with paraplegia: considerations for shoulder health. *Spinal Cord*. 2008;46:335–343. doi:10.1038/sj.sc.3102140
31. Rockwood CAJ, Matsen FAI, Wirth MA, Lippit SB. *The shoulder*. 3rd ed. Philadelphia: Saunders, 2004.
32. Royer PJ, Kane EJ, Parks KE, Morrow JC, Moravec RR, Christie DS, Teyhen DS. Fluoroscopic assessment of rotator cuff fatigue on glenohumeral arthrokinematics in shoulder impingement syndrome. *J Shoulder Elbow Surg*. 2009;18:968–975. doi:10.1016/j.jse.2009.03.002
33. San Juan JG, Karduna R. Measuring humeral head translation using fluoroscopy: A validation study. *J Biomech*. 2010;43:771–774. doi:10.1016/j.jbiomech.2009.10.034
34. Schaubert KL, Bohannon RW. Reliability and validity of three strength measures obtained from community-dwelling elderly persons. *J Strength Cond Res*.2005;19:717–720. doi:10.1519/R-15954.1
35. Shanahan EM, Ahern M, Smith M, Wetherall M, Bresnihan B, FitzGerald O. Suprascapular nerve block (using bupivacaine and methylprednisolone acetate) in chronic shoulder pain. *Ann Rheum Dis*. 2003;62:400–406. PubMed doi:10.1136/ard.62.5.400
36. Sharkey NA, Marder RA. The rotator cuff opposes superior translation of the humeral head. *Am J Sports Med*. 1995;23:270–275. PubMed doi:10.1177/036354659502300303
37. Soslowsky LJ, Carpenter JE, Bucchieri JS, Flatow EL. Biomechanics of the rotator cuff. *Orthop Clin North Am*. 1997;28:17–30. PubMed doi:10.1016/S0030-5898(05)70261-3
38. Steenbrink F, de Groot JH, Veeger HE, van der Helm FC, Rozing PM. Glenohumeral stability in simulated rotator cuff tears. *J Biomech*. 2009. doi:10.1016/j.jbiomech.2009.04.011
39. Suprak DN, Osternig LR, van Donkelaar P, Karduna AR. Shoulder joint position sense improves with elevation angle in a novel, unconstrained task. *J Orthop Res*. 2006;24:559–568. PubMed doi:10.1002/jor.20095
40. Tan N, Agnew NM, Scawn ND, Pennefather SH, Chester M, Russell GN. Suprascapular nerve block for ipsilateral shoulder pain after thoracotomy with thoracic epidural analgesia: a double-blind comparison of 0.5% bupiva-

caine and 0.9% saline. *Anesth Analg*. 2002;94:199–202. doi:10.1097/00000539-200201000-00038

41. Terrier A, Reist A, Vogel A, Farron A. Effect of supraspinatus deficiency on humerus translation and glenohumeral contact force during abduction. *Clin Biomech (Bristol, Avon)*. 2007;22:645–651. doi:10.1016/j.clinbiomech.2007.01.015
42. Teyhen DS, Christ TR, Ballas ER, Hoppes CW, Walters, JD, Christie DS, Dreitzler G, Kane EJ. Digital fluoroscopic video assessment of glenohumeral migration: Static vs. dynamic conditions. *J Biomech*. 2010;43:1380–1385. doi:10.1016/j.jbiomech.2010.01.026
43. Teyhen DS, Miller JM, Middag TR, Kane EJ. Rotator cuff fatigue and glenohumeral kinematics in participants without shoulder dysfunction. *J Athl Train*. 2008;43:352–358. PubMed doi:10.4085/1062-6050-43.4.352
44. Thompson WO, Debski RE, Boardman ND, 3rd, et al. A biomechanical analysis of rotator cuff deficiency in a cadaveric model. *Am J Sports Med*. 1996;24:286–292. PubMed doi:10.1177/036354659602400307
45. Tsai NT, McClure PW, Karduna AR. Effects of muscle fatigue on 3-dimensional scapular kinematics. *Arch Phys Med Rehabil*. 2003;84:1000–1005. PubMed doi:10.1016/S0003-9993(03)00127-8
46. Wattanaprakornkul D, Halaki M, Boettcher C, Cathers I, Ginn KA. A comprehensive analysis of muscle recruitment patterns during shoulder flexion: an electromyographic study. *Clin Anat*. 2011;24:619–626. PubMed doi:10.1002/ca.21123
47. Werner CM, Weishaupt D, Blumenthal S, Curt A, Favre P, Gerber C. Effect of experimental suprascapular nerve block on active glenohumeral translations in vivo. *J Orthop Res*. 2006;24:491–500. PubMed doi:10.1002/jor.20011
48. Williams GR, Kelley M. Management of Rotator Cuff and Impingement Injuries in the Athlete. *J Athl Train*. 2000;35:300–315. PubMed
49. Wong AS, Gallo L, Kuhn JE, Carpenter JE, Hughes RE. The effect of glenoid inclination on superior humeral head migration. *J Shoulder Elbow Surg*. 2003;12:360–364. PubMed doi:10.1016/S1058-2746(03)00026-0
50. Yamaguchi K, Sher JS, Andersen WK, et al. Glenohumeral motion in patients with rotator cuff tears: a comparison of asymptomatic and symptomatic shoulders. *J Shoulder Elbow Surg*. 2000;9:6–11. PubMed doi:10.1016/S1058-2746(00)90002-8