

THE FLOATING SHOULDER: A BIOMECHANICAL BASIS FOR CLASSIFICATION AND MANAGEMENT

BY GERALD R. WILLIAMS JR., MD, JOHN NARANJA, MD, JOHN KLIMKIEWICZ, MD, ANDREW KARDUNA, PHD,
JOSEPH P. IANNOTTI, MD, PHD, AND MATTHEW RAMSEY, MD

*Investigation performed at the Shoulder and Elbow Service, Department of Orthopaedic Surgery,
University of Pennsylvania School of Medicine, Philadelphia, Pennsylvania*

Background: The floating shoulder (ipsilateral fractures of the clavicular shaft and the scapular neck) is thought to be an unstable injury pattern requiring operative stabilization in most instances. This recommendation has been made with little biomechanical data to support it. The purpose of this study was to determine the osseous and ligamentous contributions to the stability of experimentally created scapular neck fractures in a cadaver model.

Methods: Standardized scapular neck fractures were made in twelve fresh-frozen human cadaveric shoulders. Each specimen was mounted in a specially designed testing apparatus and secured to a standard materials testing device. In group 1 (six shoulders), resistance to medial displacement was determined following sequential creation of an ipsilateral clavicular fracture, coracoacromial ligament disruption, and acromioclavicular capsular disruption. In group 2 (six shoulders), resistance to medial displacement was determined following sequential sectioning of the coracoacromial and coracoclavicular ligaments.

Results: The average measured force for all specimens (groups 1 and 2) after scapular neck fracture was 183 ± 3.3 N (range, 166 to 203 N). The addition of a clavicular fracture (group 1) resulted in an average measured force of 128 ± 10.5 N (range, 83 to 153 N), which corresponds to only a 30% loss of stability. Subsequent sectioning of the coracoacromial and acromioclavicular capsular ligaments yielded an average force of 126 ± 9.1 N (range, 114 to 144 N), a 31% loss of stability, and 0 N, a complete loss of stability, respectively. Sectioning of the coracoacromial and coracoclavicular ligaments after scapular neck fracture (group 2) resulted in an average force of 103 ± 8.4 N (range, 89 to 118 N), a 44% loss of stability, and 0 N, a complete loss of stability, respectively.

Conclusions: Ipsilateral fractures of the scapular neck and the clavicular shaft do not produce a floating shoulder without additional disruption of the coracoacromial and acromioclavicular capsular ligaments. These and other unstable combined injury patterns are likely to be accompanied by substantial medial displacement of the glenoid fragment.

Clinical Relevance: Operative stabilization of ipsilateral fractures of the scapular neck and the clavicular shaft may not be necessary in the absence of concomitant injury to the coracoacromial and acromioclavicular ligaments characterized by marked medial displacement.

Goss introduced the concept of the superior shoulder suspensory complex to elucidate the pathoanatomy of certain shoulder injuries¹⁻³. The superior shoulder suspensory complex consists of a bone and soft-tissue ring (the glenoid, coracoid process, coracoclavicular ligament, distal part of the clavicle, acromioclavicular joint, and acromion process) (Fig. 1). Disruptions of one component of the superior shoulder suspensory complex are relatively common and do not compromise its overall suspensory function. However, double disruptions of the superior shoulder suspensory complex are thought to be unstable and may require operative stabilization. One such double disruption is ipsilateral fractures of the clavicle and the scapular neck, or the so-called floating shoulder⁴⁻⁷.

Scapular or glenoid neck fracture fragments are attached to the clavicle by the coracoclavicular ligament (Fig. 2). In the presence of an ipsilateral fracture of the clavicular shaft (that is, a floating shoulder), the glenoid has lost its attachment to the axial skeleton. However, it is still attached to the acromion by the coracoacromial ligament and, through the coracoclavicular ligament and the distal clavicular fragment, by the acromioclavicular capsular ligaments (Fig. 3).

Recommendations for operative stabilization of floating shoulders have been made without supportive biomechanical data to indicate the factors contributing to stability of scapular neck fractures. The purposes of the present biomechanical study of human cadavera were to determine the con-

tributions of the clavicular shaft and the coracoacromial, coracoclavicular, and acromioclavicular capsular ligaments to stability of experimentally created scapular neck fractures and to test the hypothesis that ipsilateral fractures of the scapular neck and the clavicular shaft do not produce a floating distal scapular neck fragment (that is, a floating shoulder) in the absence of additional disruptions of the coracoacromial and acromioclavicular attachments to the glenoid.

Materials and Methods

Thirteen fresh-frozen, unpaired human cadaveric shoulders were used in this study. The average age of the donors at the time of death was seventy-four years (range, seventy to eighty-one years). The shoulders were thawed to room temperature. Skin, subcutaneous tissue, and all muscles were removed, and the glenohumeral joints were disarticulated. This left thirteen osseoligamentous preparations consisting of the clavicle, the scapula, and the coracoclavicular, coracoacromial, and acromioclavicular capsular ligaments available for testing. During testing, the shoulders were kept moist with a protease-inhibitor solution to minimize specimen degradation⁸.

In each specimen, a standardized hole was drilled and tapped in the center of the glenoid fossa perpendicular to the glenoid face. Cancellous bone was removed from the glenoid vault with a curet, and the vault was filled with Bondo automobile-body filler (Dynatron/Bondo, Atlanta, Georgia). The liquid Bondo was injected into the glenoid vault with a large syringe, and the specimens were screwed onto a specially machined extension for the actuator of a standard materials testing device (MTS, Minneapolis, Minnesota). The platform of the materials testing device was then brought up to the mounted specimen so that the medial aspect of the scapula and clavicle came to rest within a metallic container that was rigidly secured to a three-degrees-of-freedom translational table. The metallic container was filled with Bondo, thereby securing the medial aspect of the scapula and clavicle to the translational table. During all testing, compressive (that is,

TABLE 1 Fractures or Equivalent Ligamentous Injuries Necessary to Produce Floating Shoulder

Fracture	Ligamentous Injury
Coracoid base	Coracoclavicular and coracoacromial
Clavicular shaft	Coracoclavicular and acromioclavicular capsular
Scapular spine (or acromion)	Coracoacromial and acromioclavicular capsular

medially directed) forces were applied to the face of the glenoid fossa and translations were not constrained along any of the three axes.

A standardized fracture of the scapular neck was created in all specimens. A high-speed burr was passed from the lateral scapular border, across the scapular neck, and out the superior scapular border at the suprascapular notch, medial to the base of the coracoid process. A 1.5-cm gap was created to allow for uninhibited displacement. The first specimen was loaded to failure, a load displacement curve was generated, and the yield point was determined. For all subsequent specimens, a force of approximately one-third the yield point (200 N) of this specimen was used to ensure testing on the elastic portion of the load displacement curve. For each of the twelve test specimens, a 200-N force was applied and the displacement was recorded. The average displacement of three trials was determined. For all subsequent testing, this average displacement was performed and the force was recorded. Prior to further testing, all specimens were cycled for fifteen repetitions. For each experimental condition, three displacement cycles were performed and the average of the three forces was determined. Each displacement cycle occurred over 3.2 sec.

Group 1

In six specimens, standardized medial displacement was per-

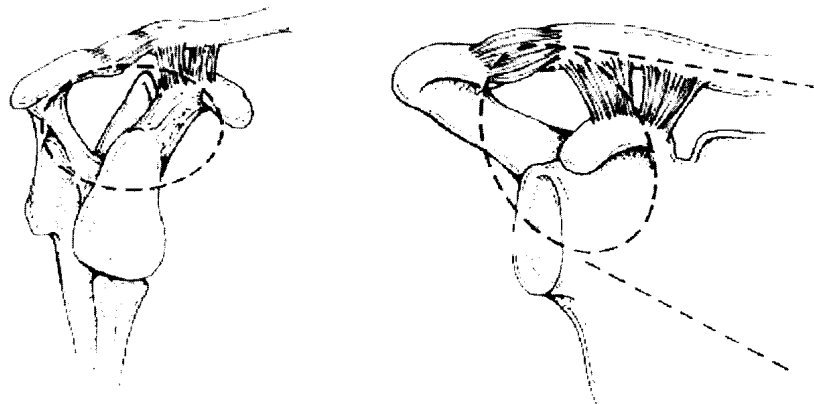


Fig. 1

The superior shoulder suspensory complex consists of a bone and soft-tissue ring (the glenoid, coracoid process, coracoclavicular ligament, distal part of the clavicle, acromioclavicular joint, and acromion process) at the end of superior and inferior osseous struts (the clavicular shaft and the lateral scapular body and spine). (Redrawn from: Goss TP. Scapular fractures and dislocations: diagnosis and treatment. *J Am Acad Orthop Surg.* 1995;3:22-33.)

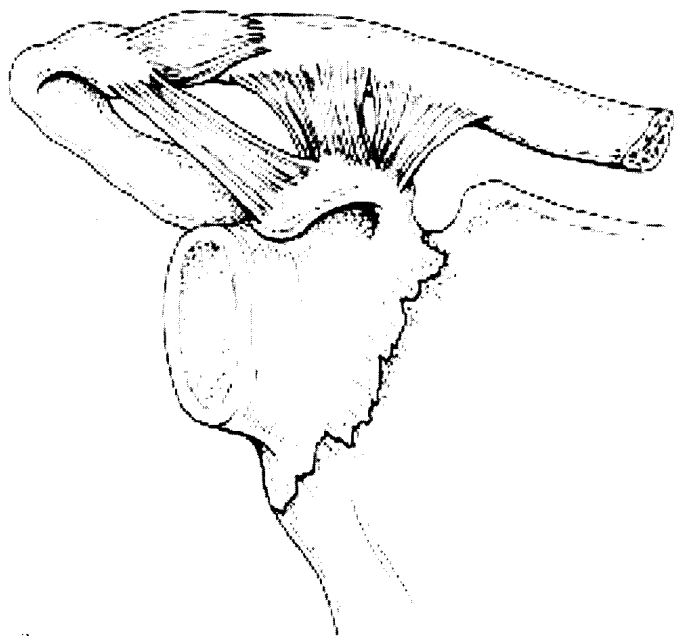

Fig. 2

Scapular or glenoid neck fractures typically produce a distal fragment consisting of the glenoid and the coracoid process and a proximal fragment consisting of the acromion, scapular spine, and scapular body. The distal fragment is still attached to the proximal fragment by the coracoacromial ligament and, through the coracoclavicular ligament and the distal clavicular fragment, by the acromioclavicular capsular ligaments.

formed after the scapular neck fracture was created, and the average force generated during three displacement cycles was determined. A clavicular fracture medial to the coracoclavicular ligament was then created with a high-speed burr. A 1.5-cm gap was made in the clavicle to allow for uninhibited displacement. The force required for displacement was then measured. Three of the six specimens then underwent sectioning of the coracoacromial ligament followed by sectioning of the acromioclavicular capsular ligaments, and the force required for displacement after each ligament sectioning was measured. The remaining three specimens in group 1 were displaced after sectioning of the acromioclavicular capsular ligaments followed by sectioning of the coracoacromial ligament, and the force required for displacement was measured (Fig. 4). At each stage (that is, clavicular fracture, single ligament disruption, and double ligament disruption), the measured force was compared with the measured force of the specimen with a scapular neck fracture only. The percentage loss of stability was calculated for each specimen, and the average of these individual percentages was calculated to represent the average loss of stability at each stage.

Group 2

In the remaining six test specimens, standardized medial displacement was performed after creation of the scapular neck fracture, and the average force generated during three displacement cycles was determined. In three of the six specimens in group 2, the force required for displacement was

measured after sequential sectioning of the coracoacromial and coracoclavicular ligaments. In the three remaining specimens, the order of sectioning was reversed and the forces required for displacement were determined (Fig. 5). At each stage (that is, single ligament disruption and double ligament disruption), the measured force was compared with the measured force of the specimen with a scapular neck fracture only. Again, the percentage loss of stability was calculated for each specimen, and the average of these percentages was calculated to represent the average loss of stability at each stage.

Results

Group 1

The average measured force for all specimens (groups 1 and 2) after scapular neck fracture was 183 ± 3.3 N (range, 166 to 203 N). The addition of a clavicular fracture resulted in an average measured force of 128 ± 10.5 N (range, 83 to 153 N), which corresponds to a 30% loss of stability. Subsequent sectioning of the coracoacromial and acromioclavicular capsular ligaments yielded average forces of 126 ± 9.1 N (range, 114 to 144 N), a 31% loss of stability, and 0 N, a complete loss of stability, respectively. Reversal of ligamentous sectioning (sectioning of the acromioclavicular capsular ligaments followed by that of the coracoacromial ligament) after clavicular fracture yielded average forces of 83 ± 28 N (range, 28 to 123 N), a 55% loss of stability, and 0 N, a complete loss of stability, respectively.

Group 2

Sectioning of the coracoacromial and coracoclavicular ligaments after scapular neck fracture resulted in an average force

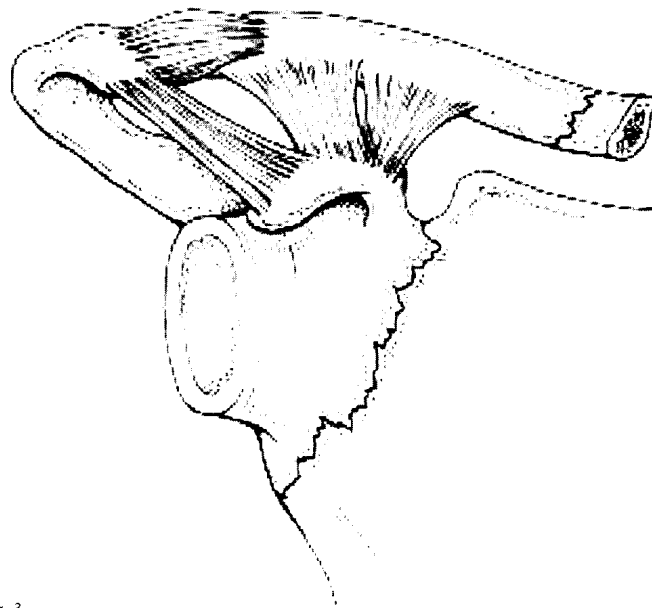


Fig. 3

In the presence of an ipsilateral fracture of the clavicular shaft (that is, a floating shoulder), the glenoid has lost its attachment to the axial skeleton. However, it is still attached to the acromion by the coracoacromial ligament and, through the coracoclavicular ligament and the distal clavicular fragment, by the acromioclavicular capsular ligaments.

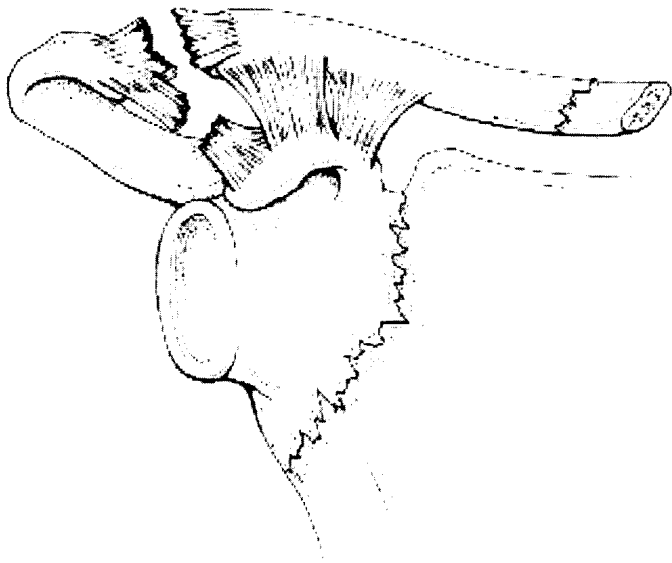

Fig. 4

In group 1, stability of scapular neck fractures was tested following an ipsilateral fracture of the clavicular shaft and disruption of the coracoacromial and acromioclavicular capsular ligaments. In three of these specimens, the coracoacromial ligament was divided before the acromioclavicular capsular ligaments. In the other three, the order of the ligament sectioning was reversed.

of 103 ± 8.4 N (range, 89 to 118 N), a 44% loss of stability, and 0 N, a complete loss of stability, respectively. Reversal of the order of ligament sectioning (sectioning of the coracoclavicular ligament followed by that of the coracoacromial ligament) resulted in an average measured force of 62 ± 10.3 N (range, 42 to 76 N), a 66% loss of stability, and 0 N, a complete loss of stability, respectively. Force displacement data for all specimens in groups 1 and 2 are depicted in Figures 6-A and 6-B.

Discussion

Ipsilateral fractures of the scapular neck and the clavicular shaft has been termed a floating shoulder because of perceived instability^{1,7}. Hardegger et al.⁴ concluded that stability of a scapular neck fracture depends on an intact clavicle and coracoclavicular ligament. They recommended stabilization of the scapular neck with a posteriorly applied semitubular buttress plate and a lag screw through the scapular spine into the neck of the scapula. Subsequent authors^{1,3,6,7} have supported the recommendation of Hardegger et al. for operative stabilization of floating shoulders. However, the recommended techniques have varied and have included isolated fixation of the clavicle, isolated fixation of the scapular neck, and combined fixation of the clavicle and the scapular neck^{1,3,6,7}.

The vast majority (>90%) of fractures of the scapular or glenoid neck exit the superior scapular border medial to the base of the coracoid process, near the suprascapular notch^{2,5,9,10}. This produces a distal fragment consisting of the glenoid and the coracoid process and a proximal fragment consisting of the acromion, scapular spine, and scapular

body. The distal fragment is attached to the proximal fragment by the coracoacromial ligament and to the axial skeleton, through the clavicular shaft, by the coracoclavicular ligament (Fig. 2).

Although the coracoacromial ligament was not included in Goss's description of the superior shoulder suspensory complex¹³, it is an important stabilizer of scapular neck fractures because it is the only direct ligamentous connection between the proximal and distal fragments. Hence, it should be included in the superior shoulder suspensory complex. Sectioning of the coracoacromial ligament in our specimens with an isolated fracture of the scapular neck (that is, those with an intact clavicle [group 2]) decreased medial stability by approximately 40%. In those specimens, the coracoclavicular ligament contributed approximately 60% of medial stability. Complete loss of medial stability (a floating distal fragment) was defined as a measured force of 0 N with medial displacement of the distal fragment. This did not occur until both of the attachments of the distal fragment to the proximal fragment and to the axial skeleton (the coracoacromial and coracoclavicular ligaments) had been disrupted.

The distal scapular neck fragment in group 1 did not lose all medial stability (that is, become floating) until both the direct attachment to the proximal fragment (the coracoacromial ligament) and the indirect attachment to the proximal fragment (the acromioclavicular capsular ligaments) were disrupted. Although we did not specifically test all potential injury patterns, our data indicate that a scapular neck fracture does not result in a floating shoulder (that is, a distal fragment) unless all attachments of the distal fragment to the proximal fragment and to the axial skeleton have also been disrupted. Clinically this can occur when a scapular

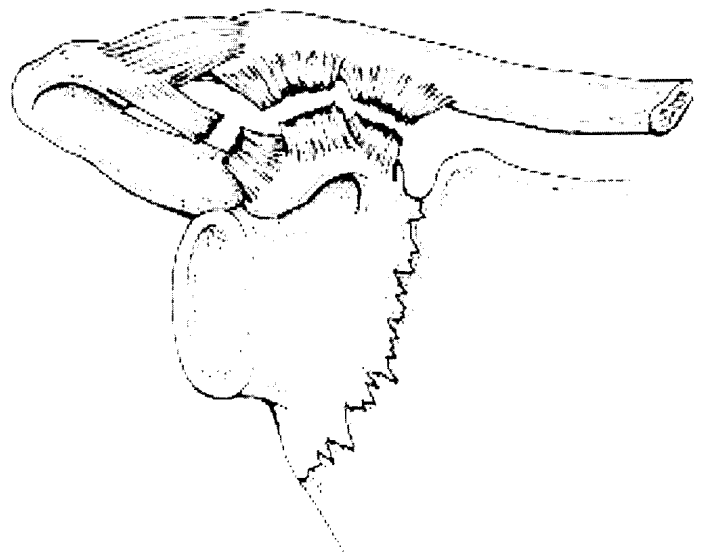


Fig. 5

In group 2, stability of scapular neck fractures was tested following disruption of the coracoacromial and coracoclavicular ligaments. In three of the specimens, the coracoacromial ligament was divided before the coracoclavicular ligament. In the other three, the order of the ligament sectioning was reversed.

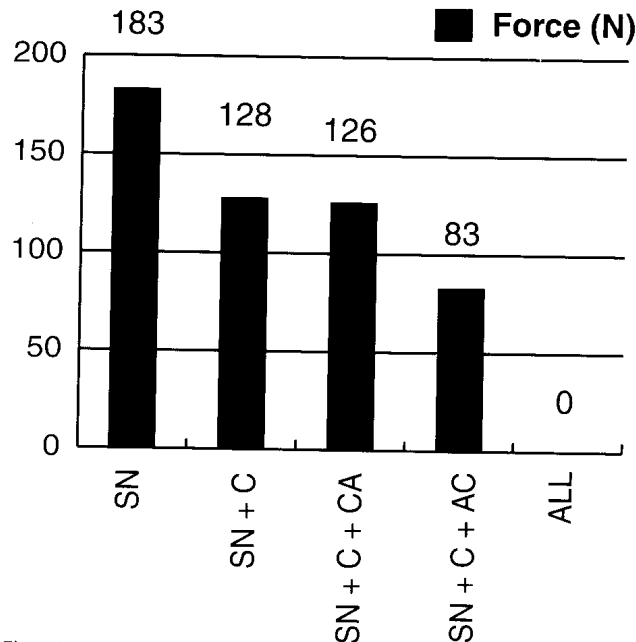


Fig. 6-A

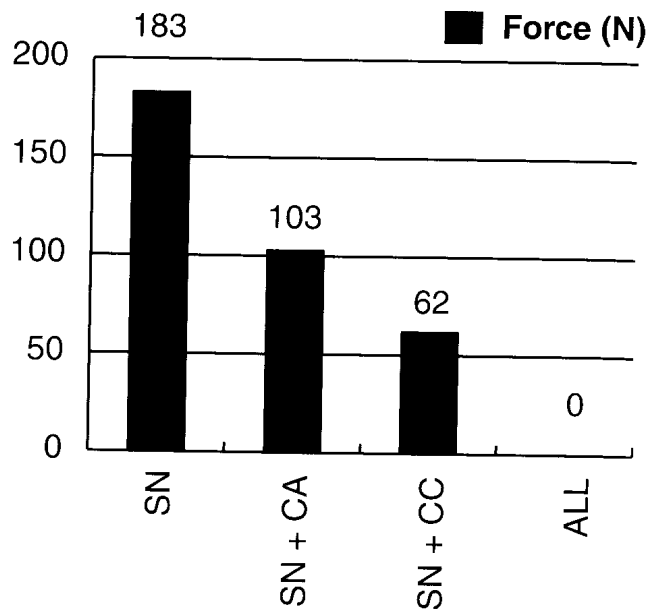


Fig. 6-B

Figs. 6-A and 6-B Force displacement data. SN = scapular neck fracture, C = clavicular fracture, CA = coracoacromial ligament sectioned, AC = acromioclavicular ligaments sectioned, and CC = coracoclavicular ligament sectioned. **Fig. 6-A** Group 1. **Fig. 6-B** Group 2.

neck fracture is accompanied by fractures of both the clavicular shaft and the scapular spine or the acromion. If only the clavicular shaft is fractured, then coracoacromial and acromioclavicular capsular ligaments must be disrupted to create a floating shoulder. Similarly, if only the scapular spine or the acromion is fractured, the coracoclavicular and acromioclavicular capsular ligaments must be disrupted. In the absence of either a clavicular fracture or a fracture of the scapular spine or the acromion, a fracture of the coracoid base results in a floating distal scapular neck fragment. In the absence of any other fracture, the coracoacromial and coracoclavicular ligaments must be disrupted to produce a floating distal scapular neck fragment. Table I lists potential fractures or equivalent ligamentous injuries necessary to produce a floating shoulder.

Our study, like any biomechanical study of cadavera, has limitations. First, our model did not include the deltoid, trapezius, rotator cuff, or other shoulder muscles that potentially contribute a dynamic stabilizing effect when a patient has fractures of the scapular neck and the clavicular shaft. Therefore, the data from our study represent a worst-case scenario with respect to stability of the scapular neck fragment. Second, the displacement force was applied in a medial direction with respect to the glenoid; therefore, it was uniaxial. This was meant to mimic the deforming forces that might be seen clinically from the compressive effect of the rotator cuff and the pectoralis major. However, it is likely that clinical deforming forces are multidirectional. Although the relative contributions of the clavicle and the coracoacromial, coracoclavicular, and acromioclavicular capsular ligaments might have been different, the disruptions necessary to produce a floating distal fragment are likely the same.

Our model was created with the assumption that the scapular neck fracture line exited the superior border of the scapula medial to the coracoid process. This is the most common pattern of scapular neck fracture. However, our data cannot be extrapolated to other types of scapular neck fractures, particularly those exiting the superior scapular border lateral to the base of the coracoid. Furthermore, there are many more potential fracture patterns involving the scapular neck, spine, and body than those discussed in our study. The categorization of unstable scapular neck fractures that we presented was not meant to be all-inclusive. It does, however, provide a logical framework, based upon biomechanical observations, for decision-making during treatment of potentially unstable fractures of the scapular neck.

Despite the limitations of our study, it is clear that ipsilateral fractures of the clavicular shaft and the scapular neck do not cause a floating shoulder without additional disruption of the coracoacromial and acromioclavicular capsular ligaments. Acromioclavicular ligament disruption is often easy to diagnose with physical examination and routine radiography. However, the physical and radiographic findings indicating a diagnosis of coracoacromial ligament disruption have yet to be determined. It is likely that ipsilateral fractures of the clavicular shaft and the scapular neck associated with disruption of the acromioclavicular capsular and coracoacromial ligaments are more displaced than are those without ligamentous disruption. In this study, we did not attempt to establish displacement criteria to indicate the need for operative stabilization of ipsilateral fractures of the clavicular shaft and the scapular neck. However, the data seem to indicate that all such fractures may not require operative stabilization. ■

Gerald R. Williams Jr., MD
Penn Orthopaedic Institute, 1 Cupp Pavilion, Presbyterian Hospital, 39th
and Market Streets, Philadelphia, PA 19104

John Naranja, MD
1608 Apple Way, Minot, ND 58701

John Klimkiewicz, MD
Department of Orthopaedic Surgery, Georgetown University, 3800 Res-
ervoir Road N.W., Washington, DC 20007

Andrew Karduna, PhD
Department of Physical Therapy, Allegheny University Hospitals,
MCP-Hahnemann School of Medicine, Broad and Vine Streets,

Philadelphia, PA 19102

Joseph P. Iannotti, MD, PhD
Department of Orthopaedic Surgery, Cleveland Clinic Foundation, 9500
Euclid Avenue, Cleveland, OH 44195

Matthew Ramsey, MD
Department of Orthopaedic Surgery, University of Pennsylvania School
of Medicine, 3400 Spruce Street, 2nd Floor, Silverstein Pavilion, Philadel-
phia, PA 19104

No benefits in any form have been received or will be received from a
commercial party related directly or indirectly to the subject of this arti-
cle. No funds were received in support of this study.

References

1. **Goss TP.** Double disruptions of the superior shoulder suspensory complex. *J Orthop Trauma.* 1993;7:99-106.
2. **Goss TP.** Fractures of the glenoid neck. *J Shoulder Elbow Surg.* 1994;3:42-52.
3. **Goss TP.** Scapular fractures and dislocations: diagnosis and treatment. *J Am Acad Orthop Surg.* 1995;3:22-33.
4. **Hardegger FH, Simpson LA, Weber BG.** The operative treatment of scapular fractures. *J Bone Joint Surg Br.* 1984;66:725-31.
5. **Herscovici D Jr, Fiennes AG, Allgower M, Ruedi TP.** The floating shoulder: ipsilateral clavicle and scapular neck fractures. *J Bone Joint Surg Br.* 1992;74:362-4.
6. **Herscovici DJ, Fiennes AG, Ruedi TP.** Ipsilateral clavicle and scapular neck fractures. *J Orthop Trauma.* 1992;6:499.
7. **Leung KS, Lam TP.** Open reduction and internal fixation of ipsilateral fractures of the scapular neck and clavicle. *J Bone Joint Surg Am.* 1993;75:1015-8.
8. **Schmidt MB, Mow VC, Chun LE, Eyre DR.** Effects of proteoglycan extraction on the tensile behavior of articular cartilage. *J Orthop Res.* 1990;8:353-63.
9. **Ada JR, Miller ME.** Scapular fractures. Analysis of 113 cases. *Clin Orthop.* 1991;269:174-80.
10. **Harmon PH, Baker DR.** Fracture of the scapula with displacement. *J Bone Joint Surg.* 1943;25:834-8.